A selection of Cervical cancer audit case reviews

Can we still learn anything from these cases?

Helen Burrell

Consultant Biomedical Scientist

Director, Bristol Cytology Training Centre

Cervical cancer audit reviews

- Do not reflect day to day screening/checking/reporting
- They are done with the knowledge that there has been a cancer diagnosis
- Heightened expectation to find ‘high grade’ cells when reviewed by individuals
- Almost impossible to rescreen without any bias/very careful approach

BAC British Association for Cytopathology

Case 1

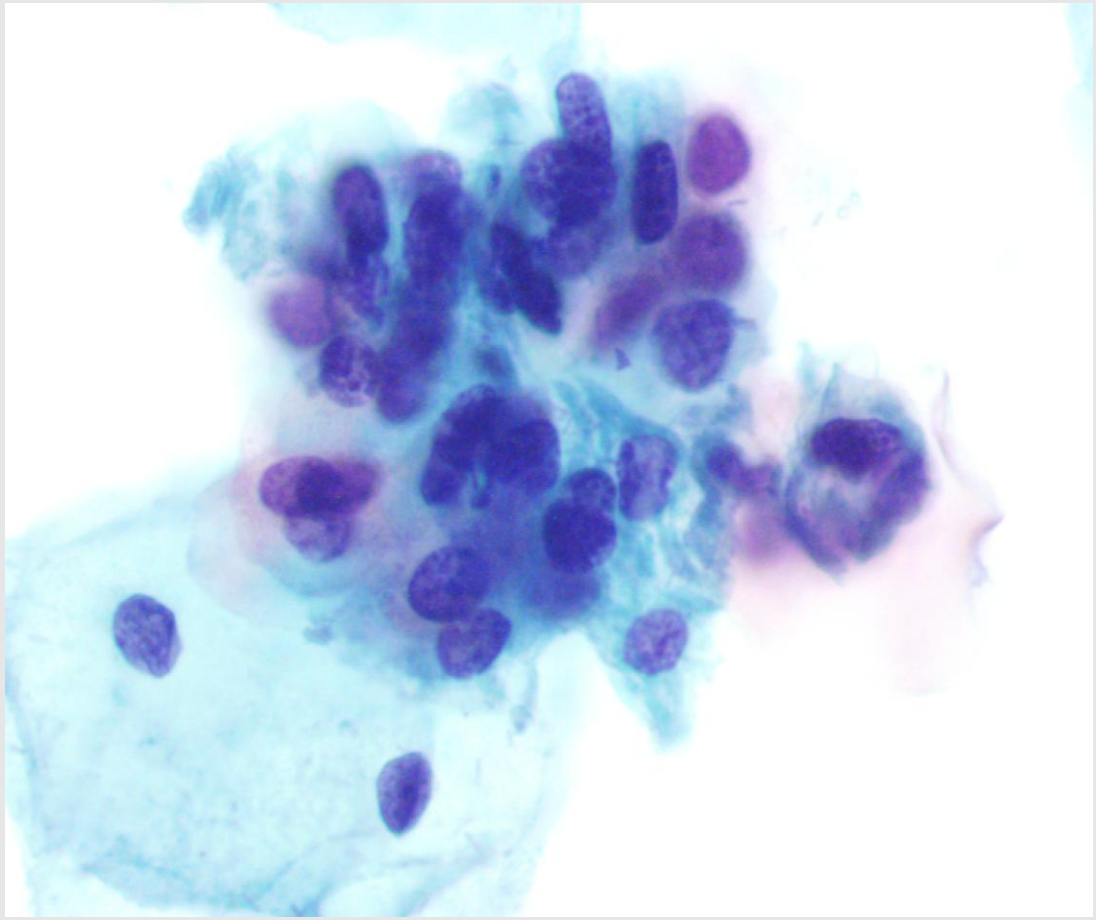

- Age 54
- Routine screen
- Negative history

BAC British Association for Cytopathology

Case 1

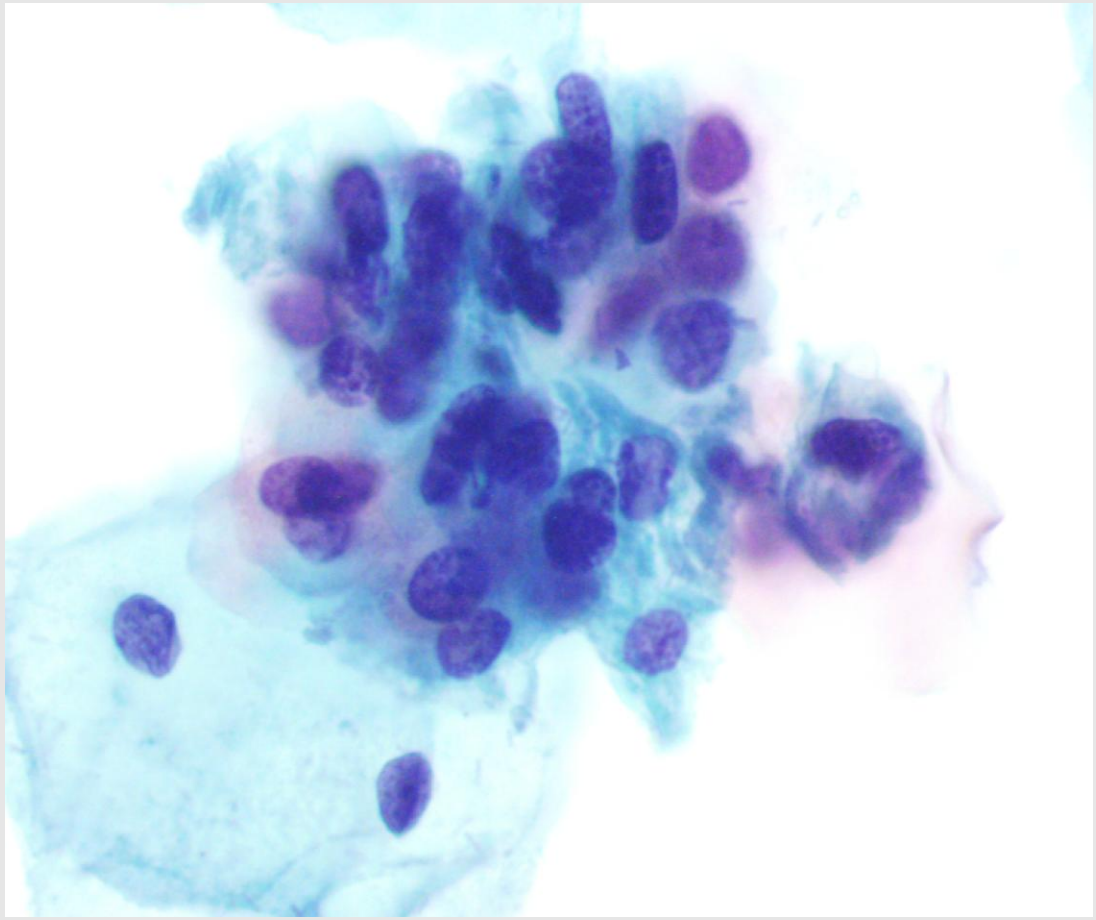

- Passed for reporting as an inflammatory sample with a few cells showing borderline changes
- Reported as borderline changes in squamous cells
- Referred to colposcopy

BAC British Association for Cytopathology

Case 1 Colposcopy

- Colposcopy was unsatisfactory
- Options for management shown in flowchart
- In view of age and patient choice, LLETZ was performed and was reported as CGIN and adenocarcinoma
- Case was reviewed as part of the cancer audit process

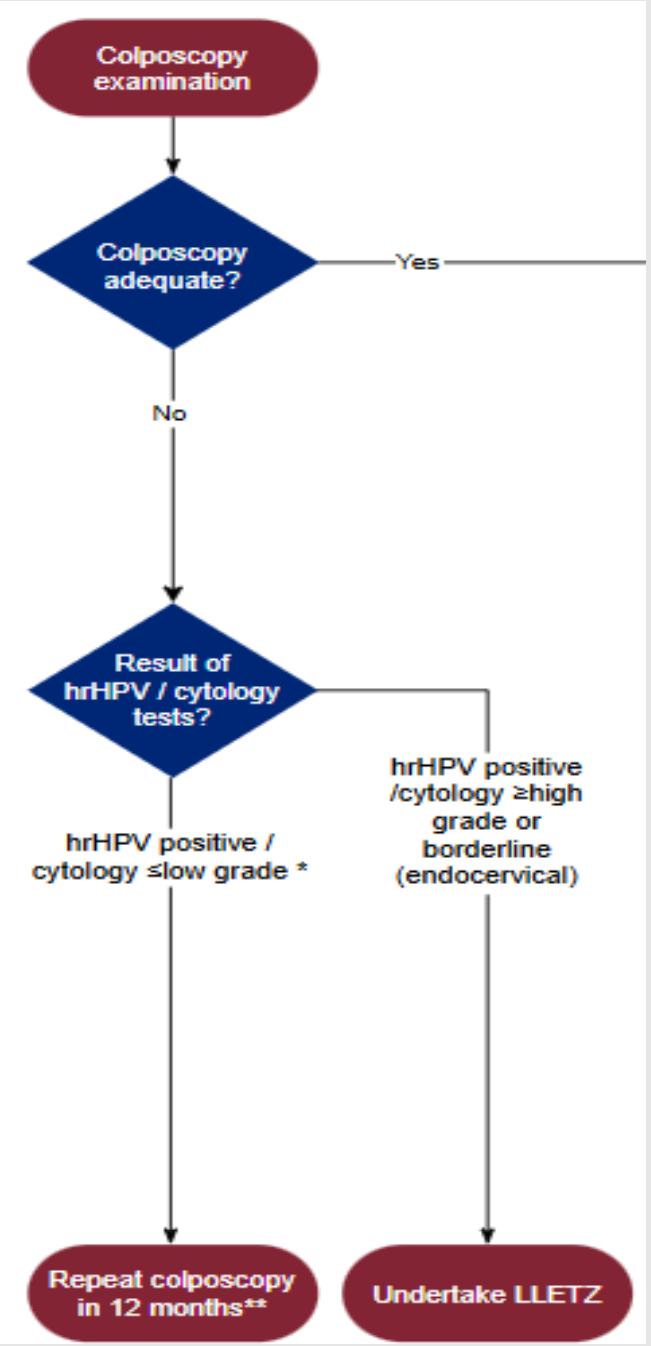

[Cervical screening care pathway - GOV.UK]

British Association for Cytopathology

Case 1 – some dark crowded groups of endocervical cells seen on review

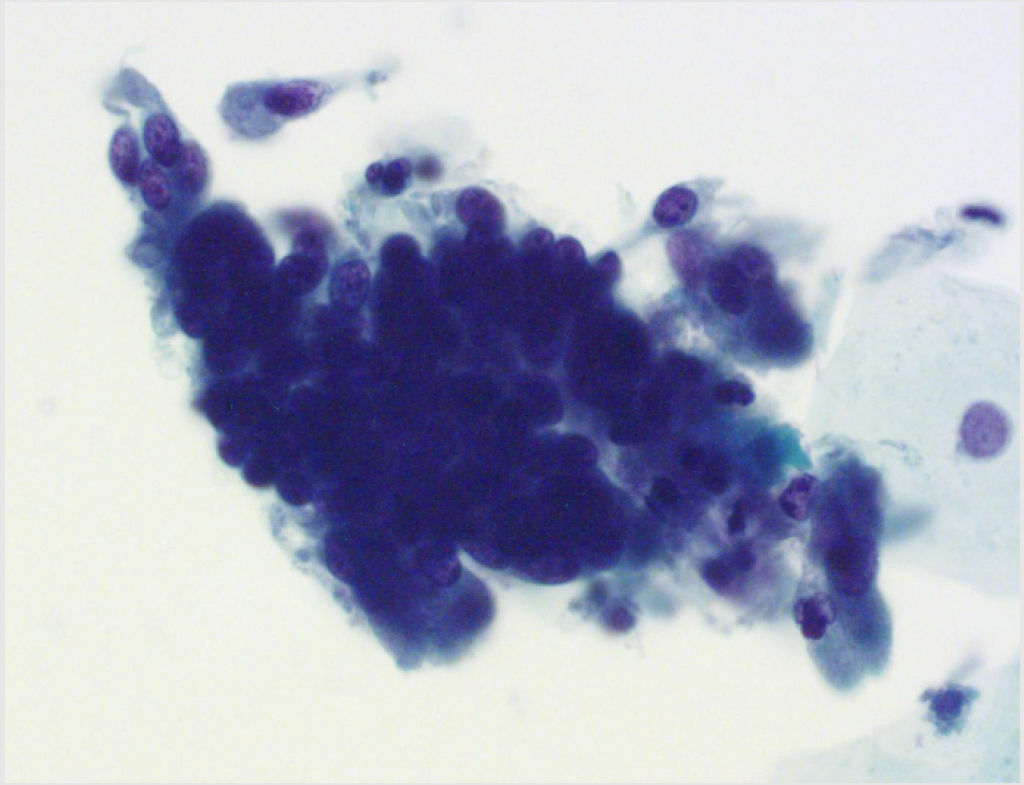

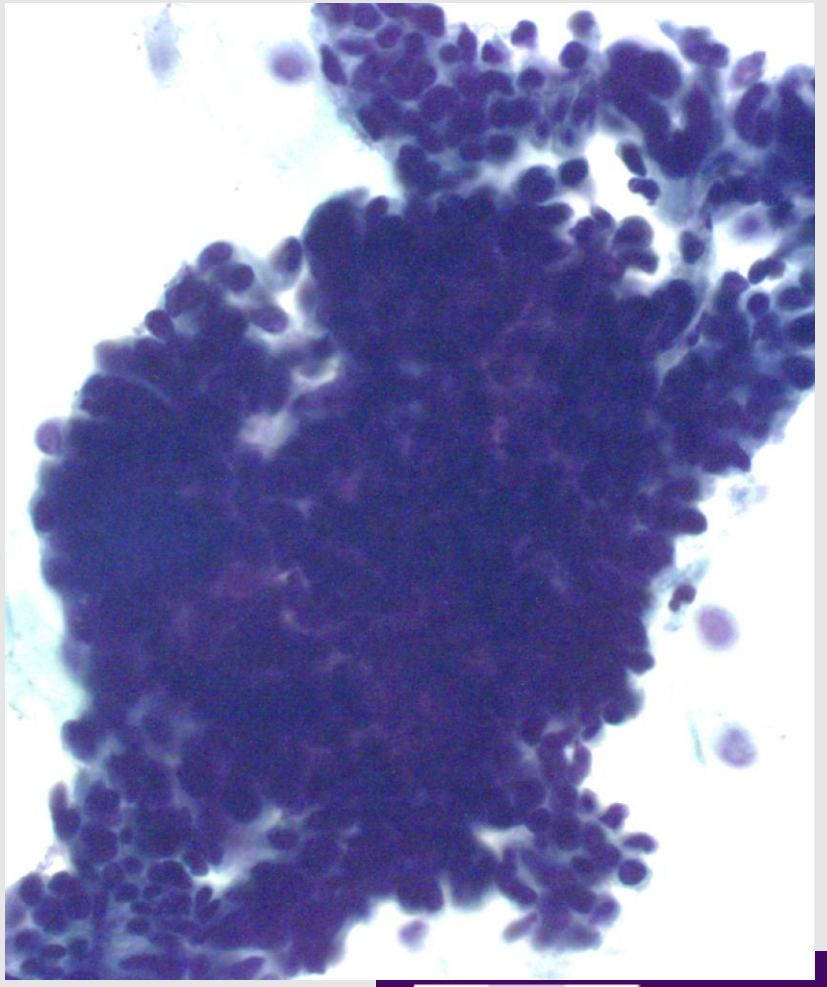

BAC British Association for Cytopathology

Review opinions

- On review the cells marked as borderline were agreed
- But there were also a couple of clusters of small endocervical cells (not originally dotted) showing marked nuclear crowding.
- Final consensus was borderline in endocervical cells

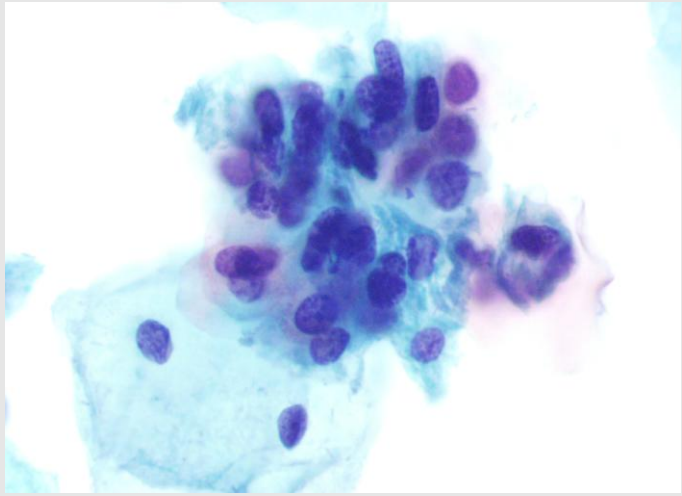

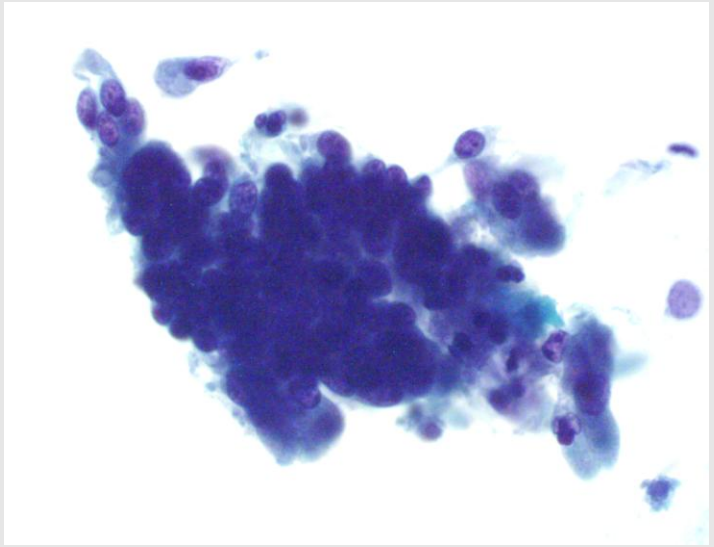

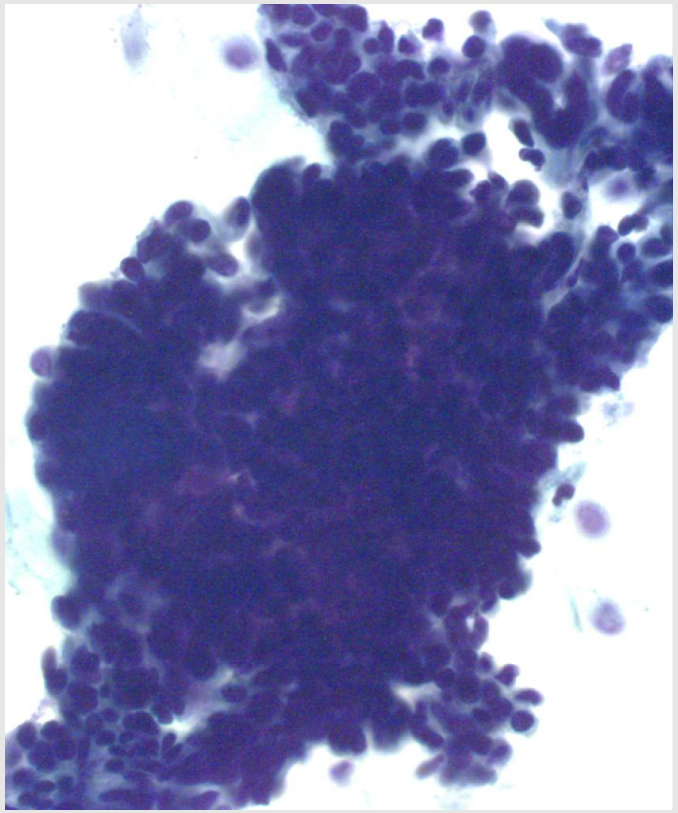

BAC British Association for Cytopathology

Case 2

- Age 39
- Referred to colp with a low-grade cytology
- Colp normal and satisfactory, patient returned to 36-month recall

- Follow up screening also low grade, referred to colposcopy
- LLETZ performed

- Reported as CGIN & Adenocarcinoma

BAC British Association for Cytopathology

Review of Low grades

- LG leading to LLETZ (no change on review, no endocervical cells present)

- Low grade from 3 years previously showed borderline/low grade, but also 2 groups of glandular cells were noted as abnormal..

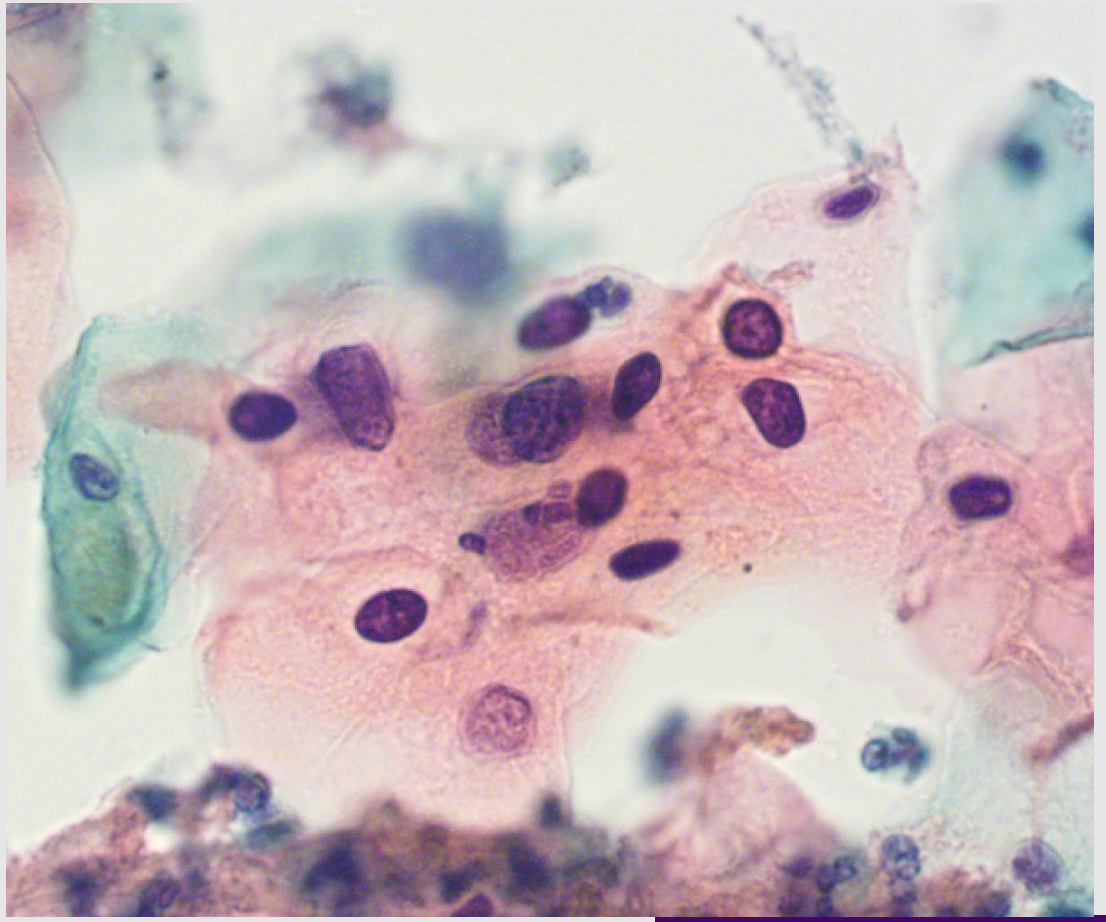

BAC British Association for Cytopathology

Reviewed as CGIN

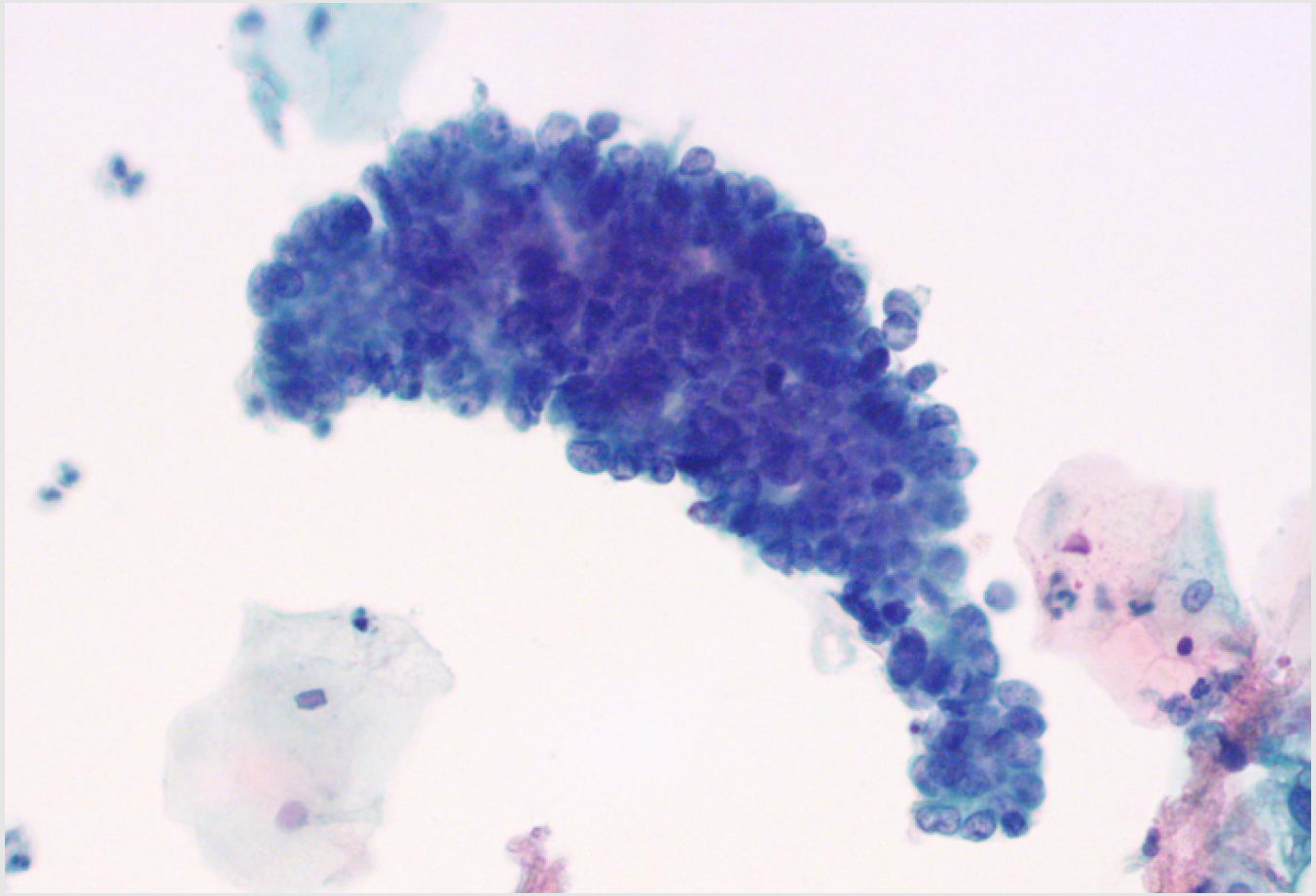

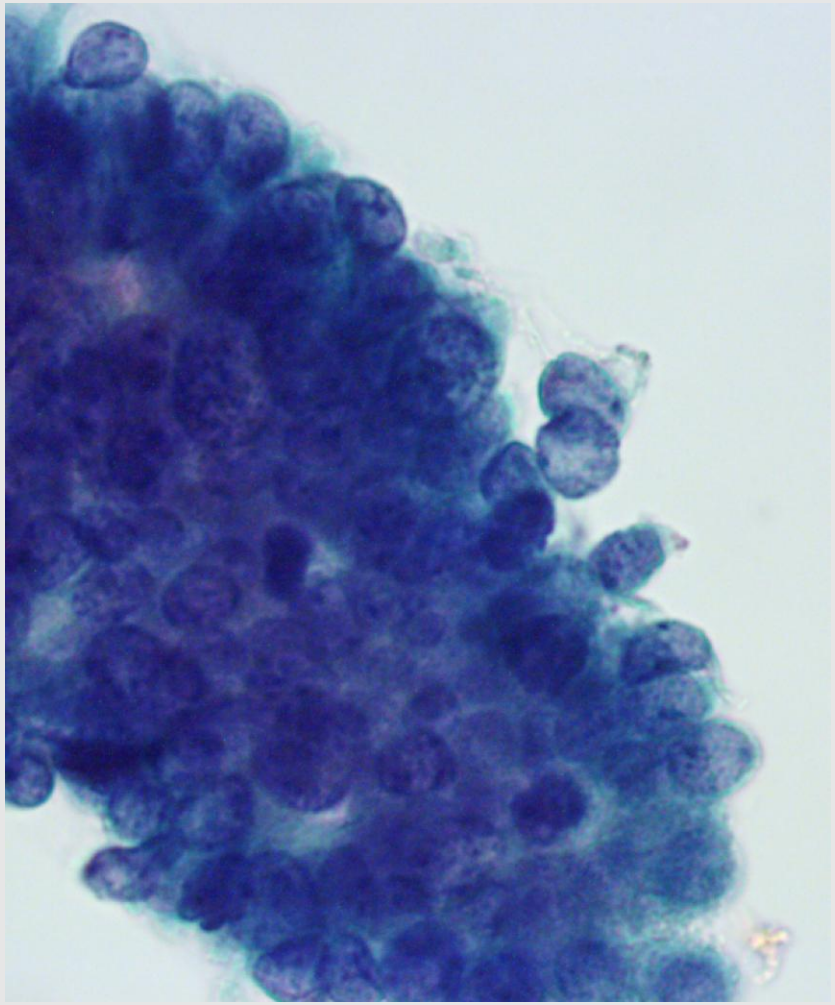

BAC British Association for Cytopathology

Cases 1& 2: learning points

- Case 1 the patient colposcopy decided to perform LLETZ when the examination of cervix was unsatisfactory
- For case 2 colposcopy was normal – remember CGIN may not be obvious at colposcopy examination. This patient would have had a LLETZ if CGIN had been picked up 3 years previously

- **Don’t lose focus when you see abnormality in squamous cells**
- **Remember closely evaluate any groups of glandular cells especially if dense**
- **Consultants must look at entire slide, not just the areas dotted**

BAC British Association for Cytopathology

Case 3

- 63-year-old
- 3rd HPV positive sample

- Screened as negative, atrophic sample, and this was agreed at rapid review

- Referred to colposcopy

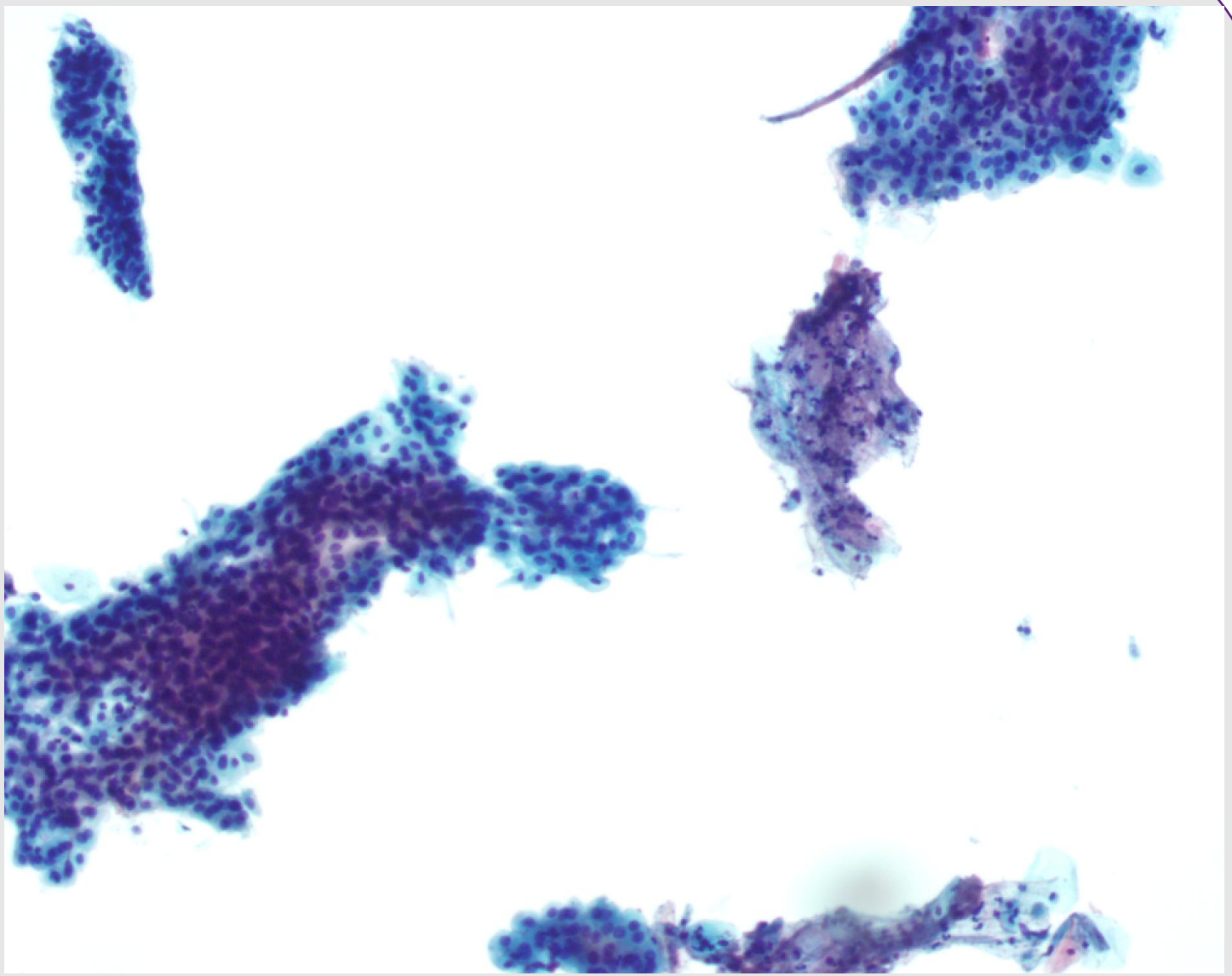

BAC British Association for Cytopathology

Case 3 Colposcopy

- TZ2, cuffed gland biopsied.
- Biopsy reported as sub-optimal but CGIN present, invasion cannot be excluded
- LLETZ performed, reported as CGIN and endocervical adenocarcinoma (SILVA B)
- Case reviewed as part of the cancer audit process

BAC British Association for Cytopathology

Case 3 – cytology review of the negative referral slide

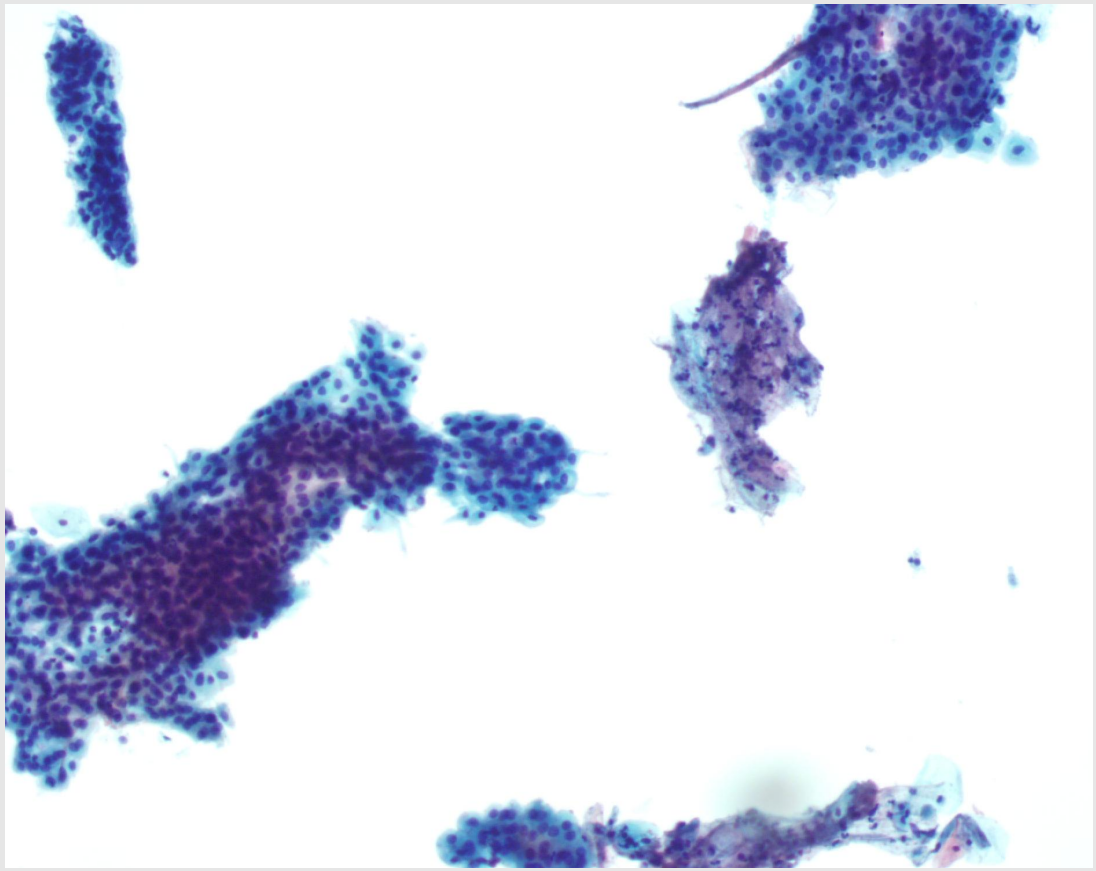

- Atrophic, numerous groups of normal parabasal cells are present.
- Occasional other groups are present that look hyperchromatic and crowded

BAC British Association for Cytopathology

Case 3 – occasional glandular groups with loss of uniformity and crowded nuclei

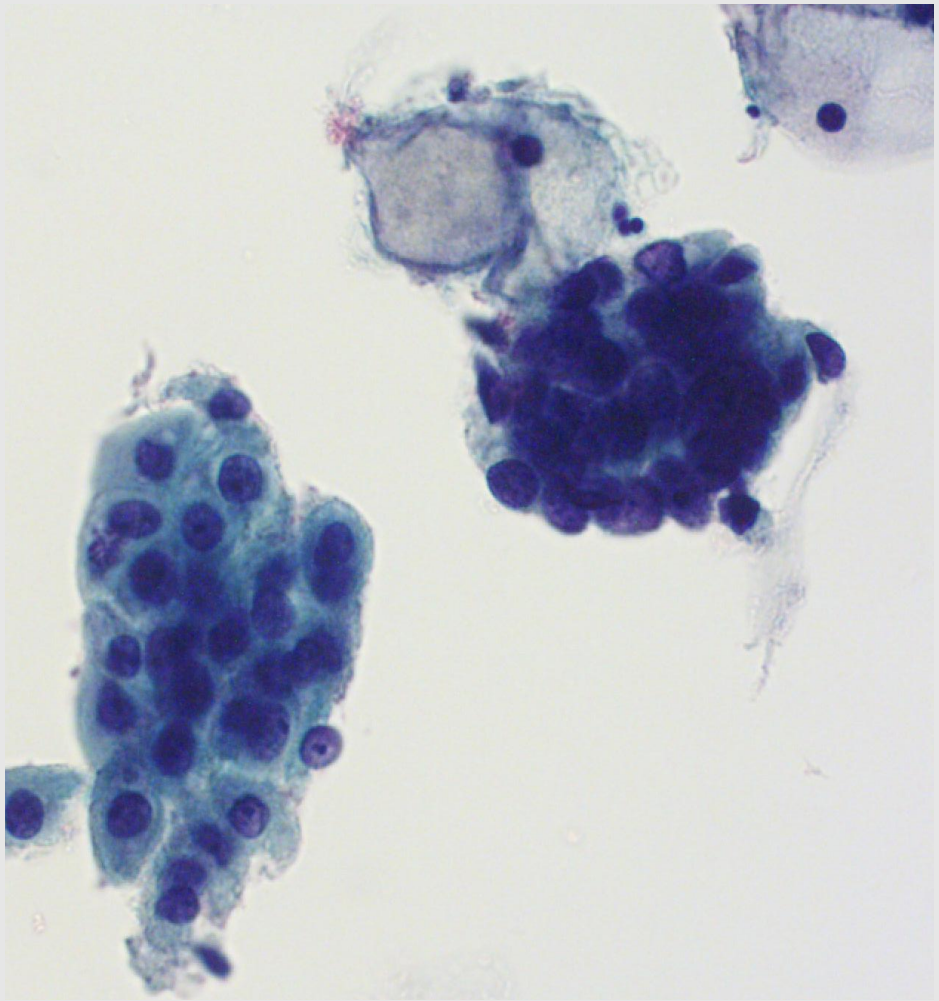

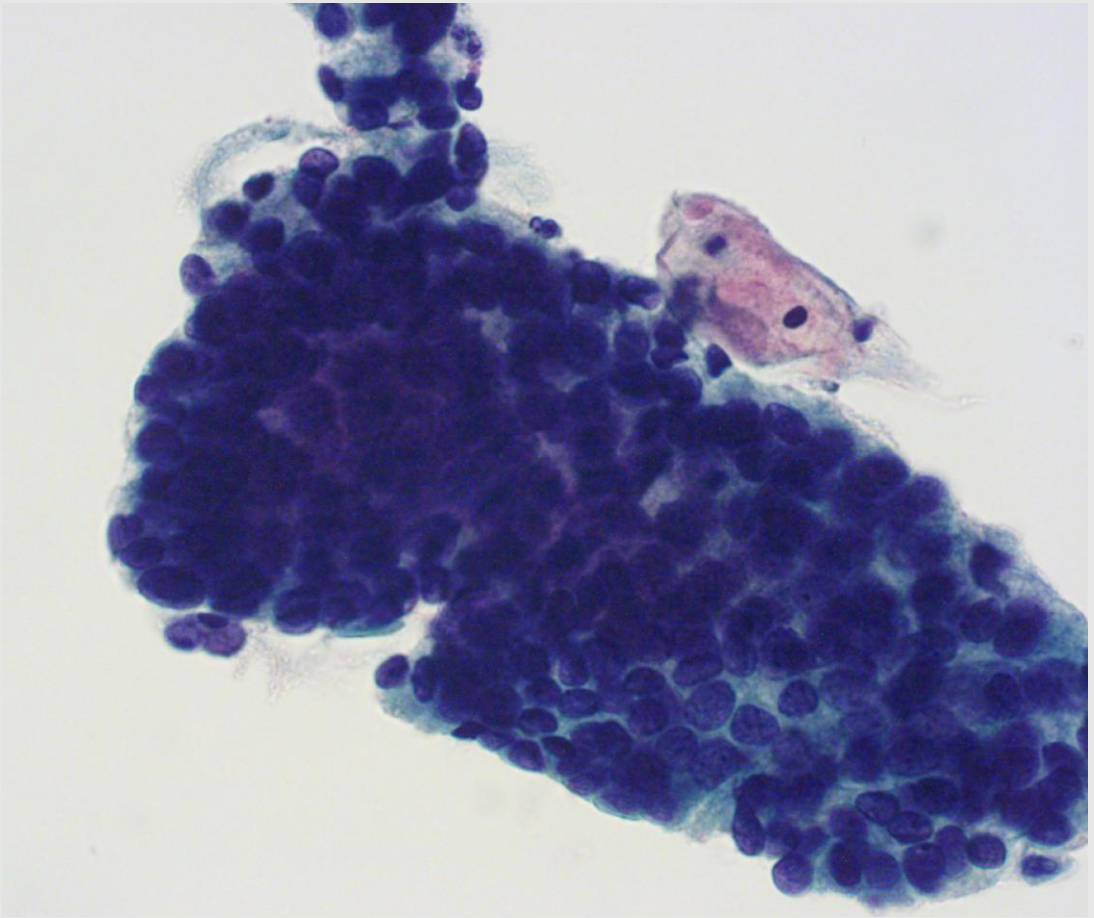

BAC British Association for Cytopathology

Case 3 consensus – Borderline in endocervical cells in an atrophic sample

- Normal parabasals

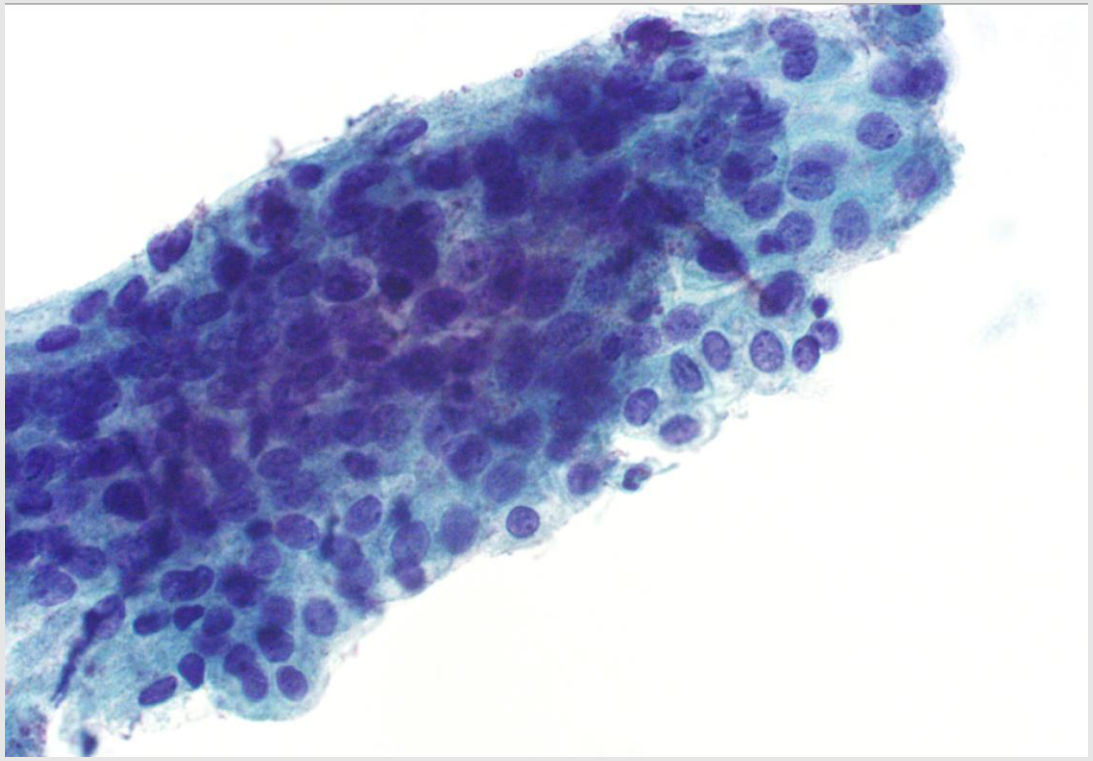

- Endocervical cells with some crowding

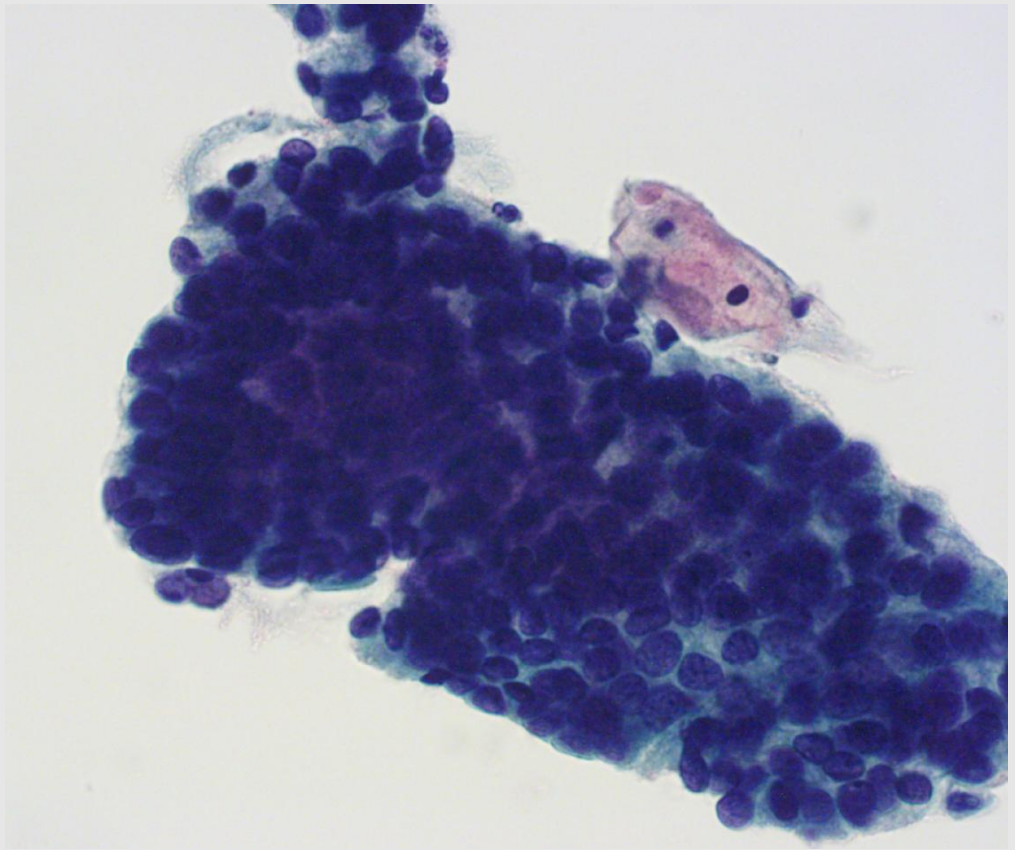

BAC British Association for Cytopathology

Case 3 Learning points

- Take care screening atrophic samples as they are composed of immature cells that often present in sheets
- Look for any groups that stand out from the background population of normal atrophy e.g. darker, more crowded, different arrangement
- **Always examine hyperchromatic crowded groups on high power**

BAC British Association for Cytopathology

Case 4

- Age 47
- Attended for 4 screening appointments

- 1st screen negative
- Last 3 screens high risk HPV not detected

- Clinical referral to colposcopy with bleeding
- Patient diagnosed with endocervical adenocarcinoma

BAC British Association for Cytopathology

Case 4 - Review of 1st screening sample from 2017

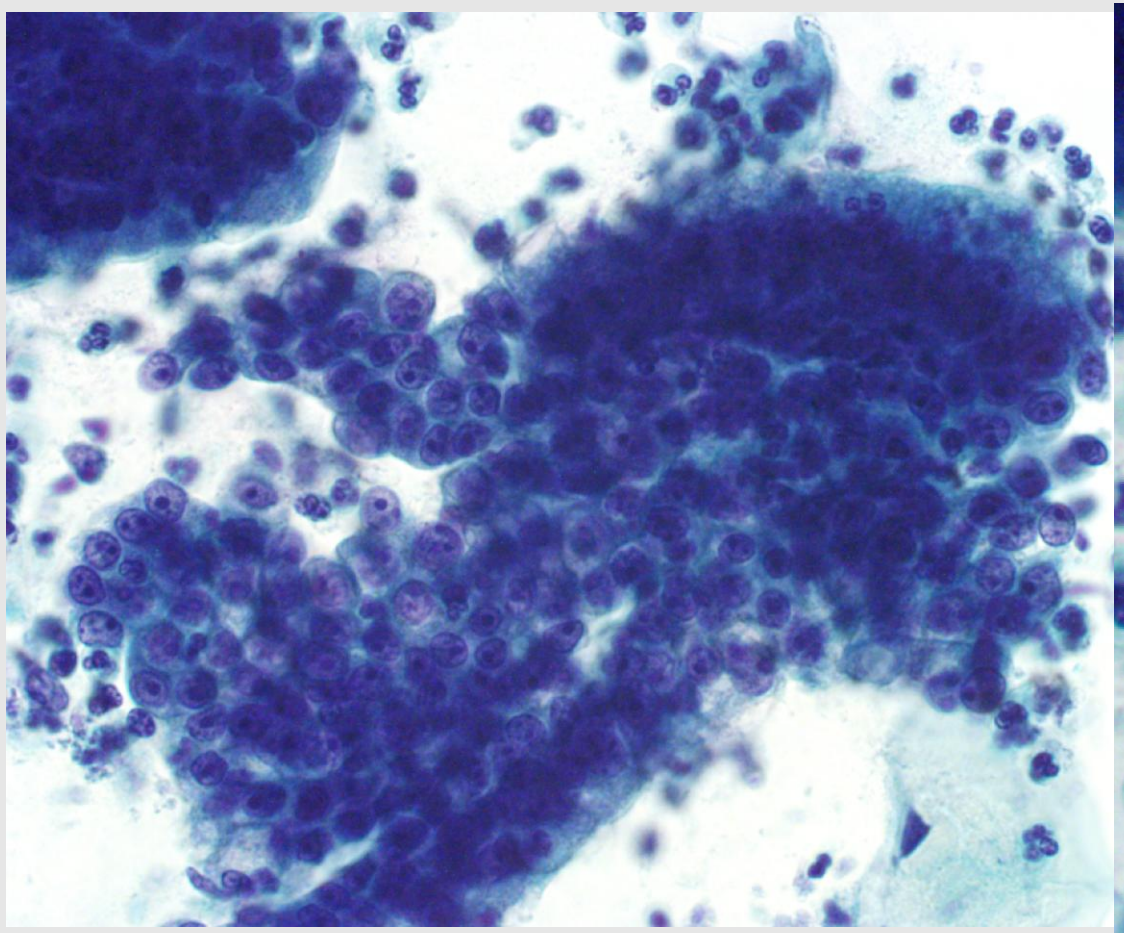

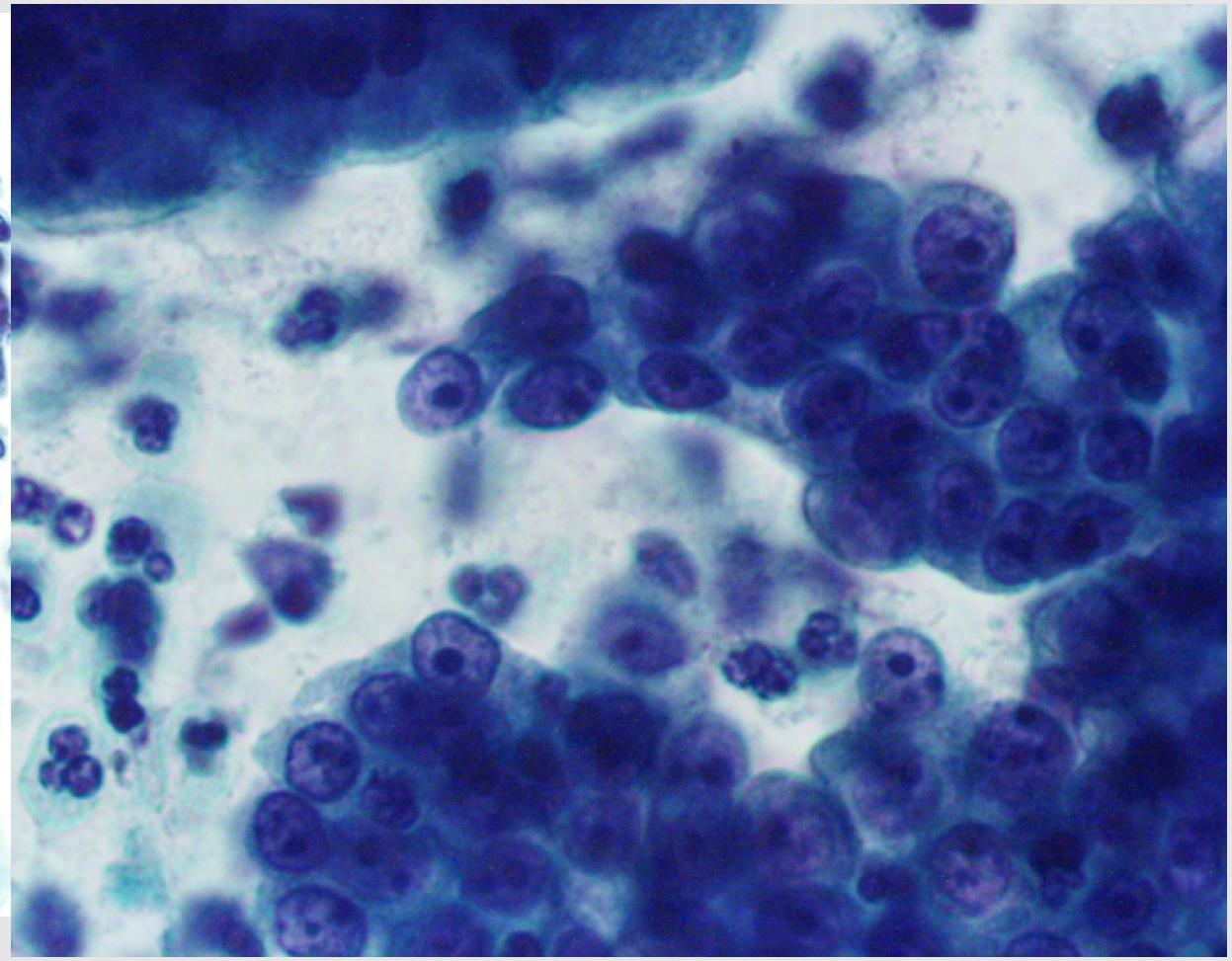

BAC British Association for Cytopathology

Case 4

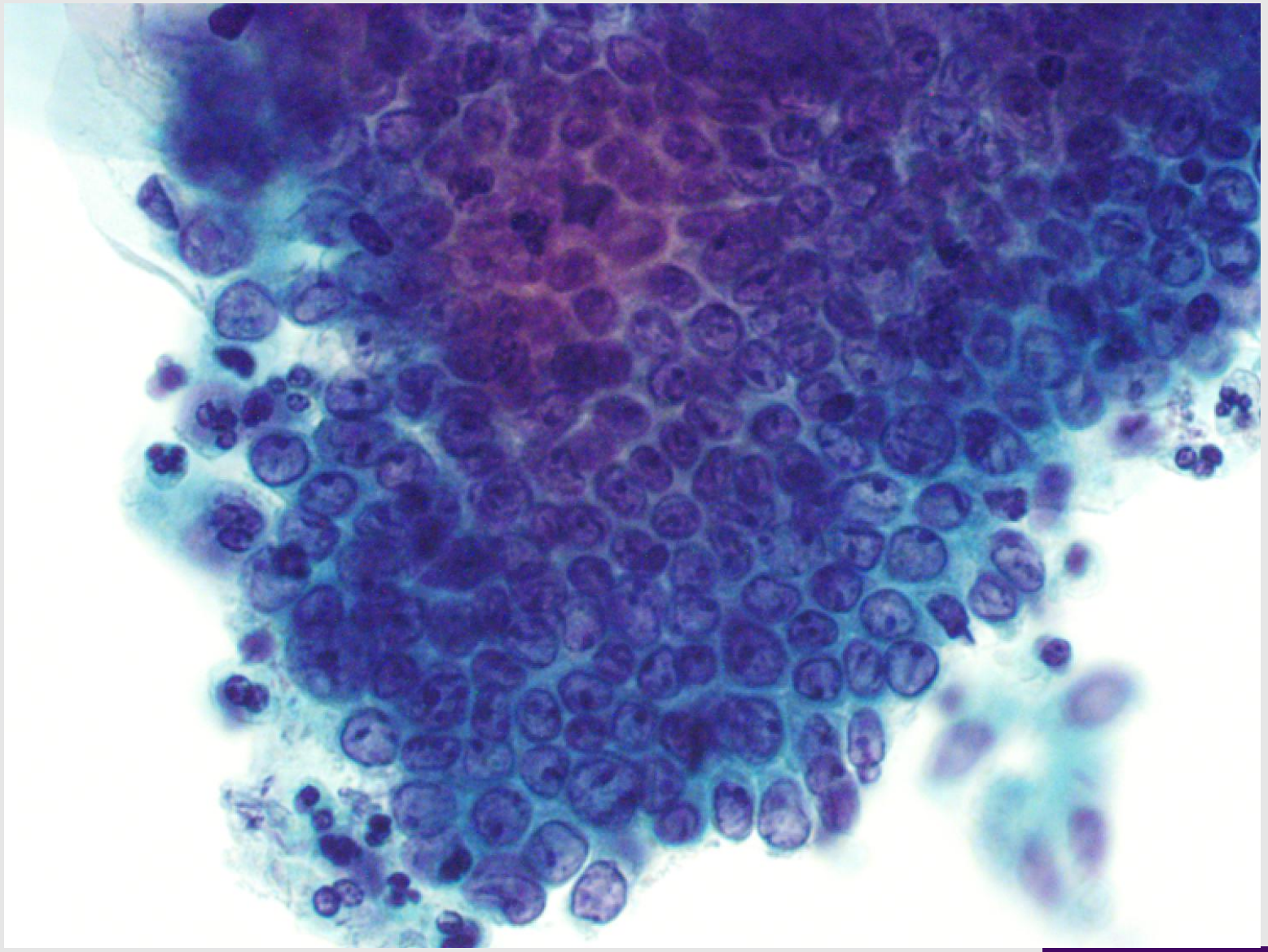

BAC British Association for Cytopathology

Case 4 Review

- HPV negative samples all valid
- 2017 cytology: Groups of glandular cells showing subtle atypia, very slight crowding in some groups with large nucleoli
- Consensus was borderline in endocervical cells given that some of the features were subtle

Further information:

- This case was confirmed histologically as a Gastric type adenocarcinoma
- HPV independent

BAC British Association for Cytopathology

Learning points

- Not all cervical cancers will be picked up by HPV testing
  - Rare
- Cytology is subtle in HPV independent cancers
- Limitation of screening

BAC British Association for Cytopathology

Are we still learning from cancer audit cases?

- Hyperchromatic crowded groups remain a problematic area
- Abnormal glandular cells can be scanty and subtle
- We may miss these groups in slides where there is co-existing squamous abnormality if we are not mindful of this
- Abnormality might not be sampled and so we cannot identify it on a slide
- We accurately screen and report most cases – **lots of slide reviews do not change from the original report**
- Colposcopy may not be able to identify endocervical abnormality
- HPV independent cancers will occur

- There are **accepted** limitations to any screening programme
- Many of the patients who develop cervical cancer are lapsed from screening or have never attended

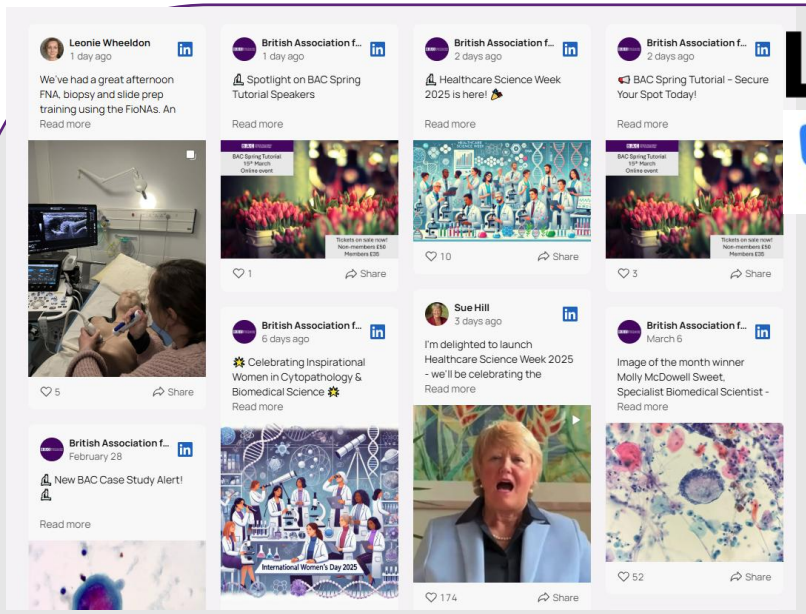

Linked in

Bluesky

The latest cytology news

Educational links
&
Guidance and publications

Win BAC goodies by submitting an image of the month, case study or blog!!



Members only access

- Reduced fees for BAC events and webinars
- Exclusive access to educational content:
  - Blogs
  - Case studies / quizzes
  - Webinars
  - SCAN magazine
  - Lunchtime slide club
- Funding and bursaries
- EFCS membership included

Consultant £125
Trainee pathologist / BMS £30
Cytoscreener £30

Up & Coming Events

16 December 2026
Members lunchtime slide club (December 2026)
Time: 12:30 - 13:00
BAC Event
Read more

13 January 2027
OCSO Healthcare Science Webinar - Leadership in Healthcare Science
Time: 12:00 - 13:00
External Organiser
Read more

24 May 2027
18th Annual EFCS Tutorial
External Organiser
Read more

Members lunchtime slide club

SCAN

Direct contact with the Executive via the website "Ask the expert section"

BAC British Association for Cytopathology



16TH DECEMBER 2026

Members lunchtime slide club (December 2026)

Time: 12:30 – 13:00

Total: **£0.00**

Buy Ticket

More Information

Free to BAC members!

Register to join the new monthly BAC Members Lunchtime Slide Club.

If you have a camera and microscope set up to live stream your case or have digital images please bring them to this session.

Talk through, share or showcase any interesting or challenging cases you might have.

This is an informal space for members to learn, grow and interact with experts.

Register today!

BAC British Association for Cytopathology